



I KATEDRA i KLINIKA KARDIOLOGII
WARSZAWSKIEGO UNIwersYTETU MEDYCZNEGO

SIGNS AND SYMPTOMS OF CARDIOVASCULAR DISEASE

Ewa Szczerba

SYMPTOM

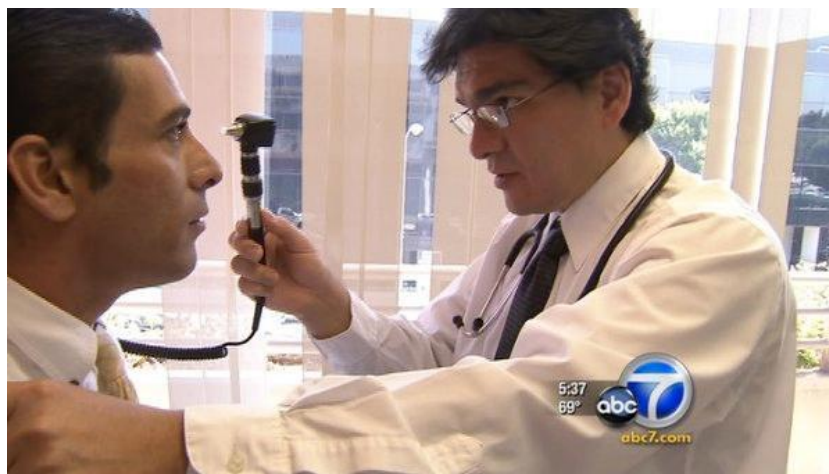any morbid phenomenon

(a symptom in relation to disease) or departure from the normal in structure, function, or sensation, **experienced by the patient** and indicative of disease



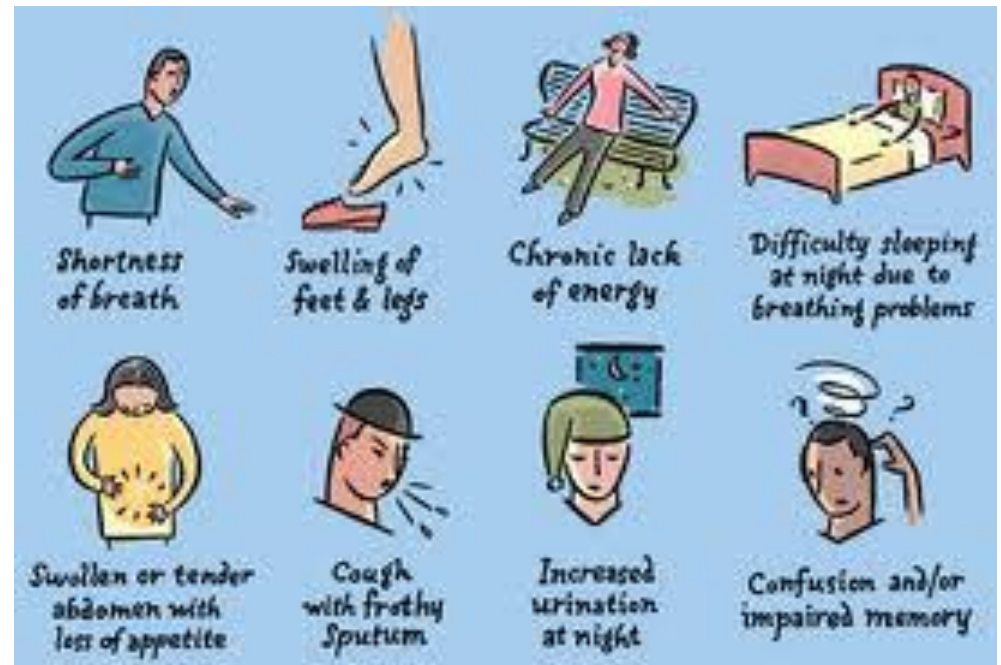SIGN

any abnormality indicative of disease, **discoverable on examination** of the patient; an **objective** symptom of disease, in contrast to a symptom which is subjective



Cardinal symptoms of heart disease

- Dyspnea
- Chest pain or discomfort
- Cyanosis
- Syncope
- Palpitations
- Oedema
- Hemoptysis
- Cough
- Exercise tolerance



Braunwald – *Heart disease* 6th edition



Case 1

- 39-year old female with no previous medical history presented to the ER with left side hemiparesis. Brain CT confirmed ischemic stroke. For 4 weeks the patient had recurrent fever up to 39 °C with chills, fatigue, anorexia, back pain in the lumbar area, and weight loss. She was treated with amoxicillin with clavulanic acid for two weeks without improvement. For 3 days she started to notice oedema of the legs, palpitations and dyspnea upon daily activities. Additionally she complains of hematuria.



Case 1

- HR 110 beats/min, BP 130/40mmHg temp 37.5 °C, RR 20/min, sat 97%
- Head and neck: blue lips; bobbing motion of the patient's head with each heartbeat
- Skin:
 - petechiae,
 - dark-red, linear lesions in the nail beds
 - tender subcutaneous nodules on the distal pads of the digits,
 - conjunctival hemorrhages



Case 1

- Heart: regular heartbeat, first heart sound diminished, second heart sound normal, decrescendo diastolic murmur loudest at the left sternal border heard best with the patient leaning forward in full expiration
- Lungs: symmetrical crackles on the basis of the lungs
- Abdomen: splenomegaly
- Pitting lower limb oedema



Infective endocarditis on aortic valve causing its insufficiency and heart failure



Symptoms of IE and HF

- left side hemiparesis
- recurrent fever up to 39 °C
- chills
- fatigue
- anorexia
- back pain in the lumbar area
- weight loss
- lower limb oedema
- palpitations
- dyspnea upon daily activities
- hematuria



Sings of IE

- tachycardia
- temp 37.5 °C
- skin:
 - petechiae,
 - dark-red, linear lesions in the nail beds - subungual (splinter) hemorrhages
 - tender subcutaneous nodules on the distal pads of the digits (Osler nodes),
 - conjunctival hemorrhages
 - nontender maculae on the palms and soles - Janeway lesions
 - retinal hemorrhages with small, clear centers - Roth spots
- splenomegaly



Sings of aortic valve insufficiency and heart failure

- tachycardia
- BP 130/40mmHg
- RR 20/min
- central cyanosis
- bobbing motion of the patient's head with each heartbeat
- diminished first heart sound due to premature closure of the mitral valve leaflets
- second heart sound normal,
- decrescendo diastolic murmur loudest at the left sternal border heard best with the patient leaning forward in full expiration
- additionally sometimes a soft, rumbling, low-pitched, late diastolic murmur which is heard best at the apex known as an Austin Flint murmur, may be detected (due to a functional mitral valve stenosis)
- symmetrical crackles on the basis of the lungs
- pitting lower limb oedema



Case 2

- 73-year old male with history of hypertension and diabetes was admitted to the ER after syncope. Syncope was preceded by a sensation of rapid heart beat with shortness of breath and stabbing pain in the Vth left intercostal space in the middle clavicular line.



Case 2

- HR 168 beats/min, BP 90/60 mmHg
temp 36.6 °C, RR 18/min, sat 95%
- Head and neck: pale skin, bruising on the back of the head, murmur over left carotid artery
- Heart: irregular heartbeat, I and II heart sound well audible and properly pronounced, no murmurs
- Lungs: normal breath sounds



Paroxysmal atrial fibrillation causing hemodynamic instability



Case 3

- 56-year old female with a history of ovarian cancer was admitted to the ER after syncope. For 3 days she had dyspnea upon exercise, chest pain on the right side of the thorax, caught and fever. Chest pain was localized between III and V intercostal space between middle and posterior axillary line, aggravated with breathing and position changes, was independent of exercise, with no radiation.



Case 3

- HR 123 beats/min, BP 100/60 mmHg, temp 37.0 °C, RR 32/min, sat 88%
- Head and neck: pale skin, blue lips
- Heart: regular heartbeat, no murmurs
- Lungs: pleural rub in the lower segment of the right lung, otherwise normal breath sounds
- Left calf - nonpitting oedema, redness, tender upon palpation.



Venous thromboembolism – DVT and PE



Case 4

- 20-year old male was admitted to the ER because of exertional dyspnea, orthopnea, paroxysmal nocturnal dyspnea, lack of appetite, and an increase of abdominal circumflex. Additionally his girlfriend notice that his eyeballs were jaundice. Asked in detail the patients said that additionally for about a week he had pale stools, darker urine and caught up dark sputum.



Case 4

- HR 118 beats/min, BP 100/60 mmHg temp 36.4 °C, RR 27/min, sat 82%
- Head and neck: blue lips and ears, jugular venous pulse,
- Skin: jaundice, clubbing of the fingers, bruising on the forearms,
- Heart: precordial palpation reveals a right ventricular heave, regular heartbeat, normal S1 and widely split S2, holosystolic harsh murmur most prominent over the lower left sternal border with radiation to the right lower sternal border
- Lungs: normal breath sounds
- Abdomen: right upper quadrant tenderness, hepatosplenomegaly, ascites
- no peripheral oedema



Eisenmenger syndrome in a patient with congenital VSD



Case 5

- 43-year old male, a smoker, with a history of hypercholesterolemia, whose father died of MI at the age of 35 was admitted to the ER because of excruciating retrosternal chest pain and jaw pain, with sudden onset, aggravating with swallowing, that started 4 h before admission. Since the onset of symptoms the retrosternal chest pain diminished but a tearing pain in the upper abdomen and intrascapular area appeared.



Case 5

- HR 90/min, BP left 200/120mmHg, BP right 120/80mmHg, temp 36.8°C, RR 18/min, sat 94%
- Skin: pale skin
- Heart: regular heartbeat, diminished heart sounds, decrescendo diastolic murmur loudest at the left sternal border
- Lungs: bibasilar crackles



Aortic root dissection with acute aortic insufficiency and pericardial fluid



Case 6

- 22-year old female with lupus presented to the ER because of aggravating dyspnea, fatigue and left-side chest pain radiating to the left arm. The patient had an upper respiratory tract infection 3 weeks ago. Since then she continues to feel sharp, burning chest pain that is worse during inspiration and when lying flat, relieved by leaning forward while seated and low-grade intermittent fever.



Case 6

- HR 100/min, BP120/80, temp 37.2 °C, RR 16/min, sat 98%
- Joints: swelling, stiffness and tenderness of knee joints
- Heart: regular heartbeat, a scratching, grating sound in the left sternal line aggravation in a leaning forward position (pericardial friction rub), diminished heart sounds, no murmurs
- Lungs: normal breath sounds
- No peripheral oedema.



Acute pericarditis



Case 7

- 43 year old women with history of hypothyroidism and breast cancer treated 10 years ago presented to the ER because of dyspnea and hemoptysis. Two year ago she had an ischemic stroke and 6 month ago pulmonary oedema. As a child the patient had streptococcal pharyngitis and tubeculosis. Dyspnea is present on exercise and during bed rest. After exercise the patient has hemoptysis.



Case 7

- HR 90-110/min, BP 110/80, temp 36.6 °C, RR 20/min, sat 92%
- Head and neck: hoarseness, blue lips, pinkish-purple patches on the cheeks, jugular vein distension
- Heart: palpable right ventricular lift, irregular heartbeat, loud first heart sound, an opening snap, a low pitched diastolic rumble, best heard at the apex with the patient in the left lateral position.
- Lungs: symmetrical crackles on the lower and medial parts of the lungs
- No peripheral oedema



Mitral stenosis



Case 8

- 85-year old women was admitted to the ER after loss of consciousness. She has been suffering from hypertension for 30 years. Additionally since 3 months she is having retrosternal, squeezing chest pain irradiating to the jaw upon exercise after walking one flight of stairs that disappear after about 1-2 minutes once she finishes exercising.



Case 8

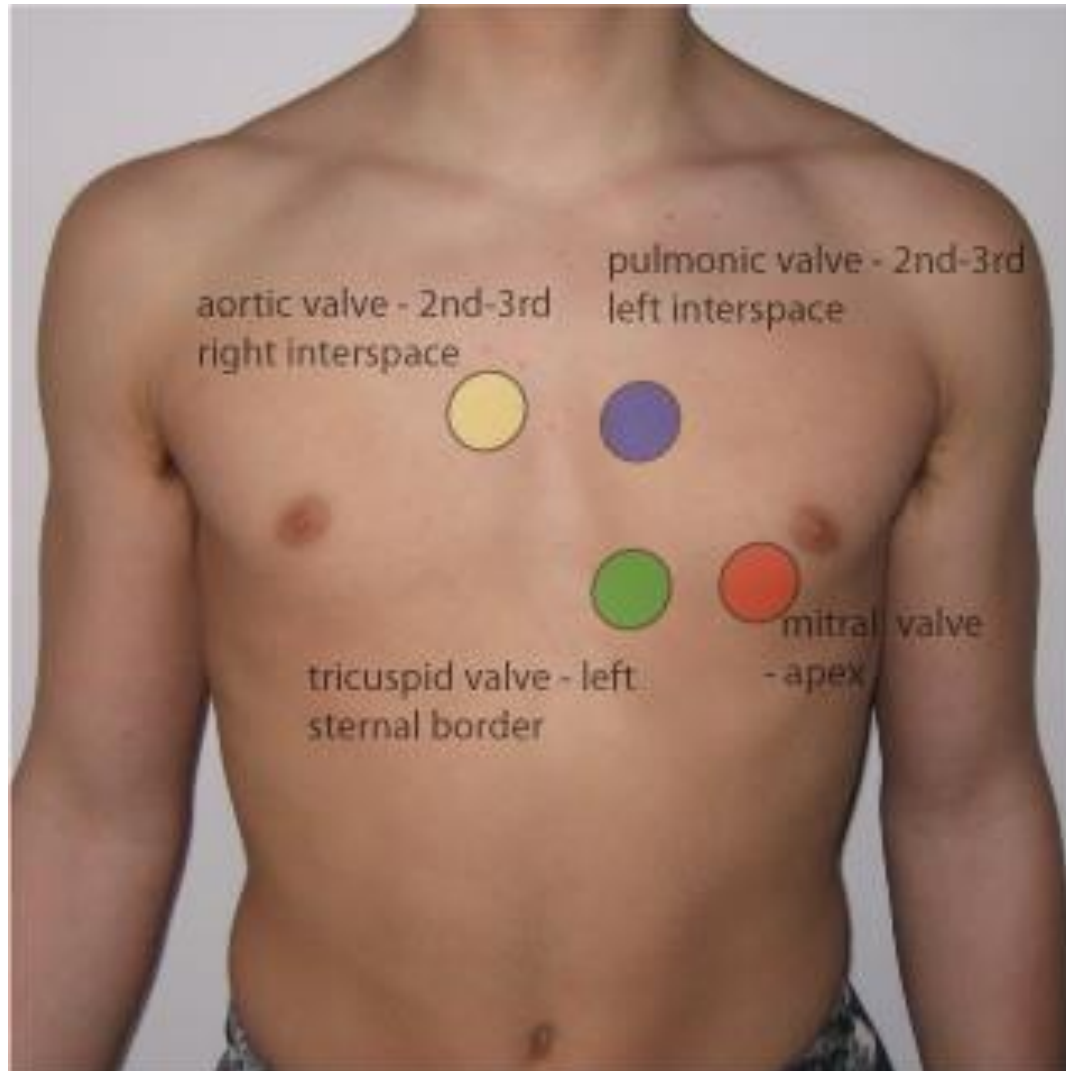
- HR 78/min, BP 160/90, temp 36.5 °C, RR 17/min, sat 96%
- Head and neck: normal
- Heart: regular heartbeats, S1 normal, absent A2 sound, prominent S4, rough, low-pitched crescendo-decrescendo systolic murmur sound that is best heard at the second intercostal space in the right upper sternal border radiating to both carotid arteries, the murmur intensity is reduced during Valsalva strain
- Lungs: crackles over lower lobes of both lungs.
- Pitting, symmetrical lower limb oedema.



Aortic stenosis



Heart auscultation



Heart sounds

- First heart sound is produced by the closing of the mitral and tricuspid valve
- Second heart sound is produced by the closing of aortic and pulmonic valve leaflets



Heart sounds

- Third heart sound is created by a sudden and rapid blood inflow to the ventricle in diastole (increased rate or volume of ventricular filling).
 - Impairment of ventricle function
 - AVR
- Fourth heart sound is created by the systole of the atria and is connected with an increased pressure in the atria. Occurs when diminished ventricular compliance increases the resistance to ventricular filling:
 - Systemic hypertension
 - Aortic stenosis
 - Hypertrophic cardiomyopathy



Heart murmurs

- Localization; side of maximal intensity
- Tone
- Timing
- Grade
- Radiation
- Relation to heart sounds (systolic, diastolic, continuous)
- Relation with posture and respiration

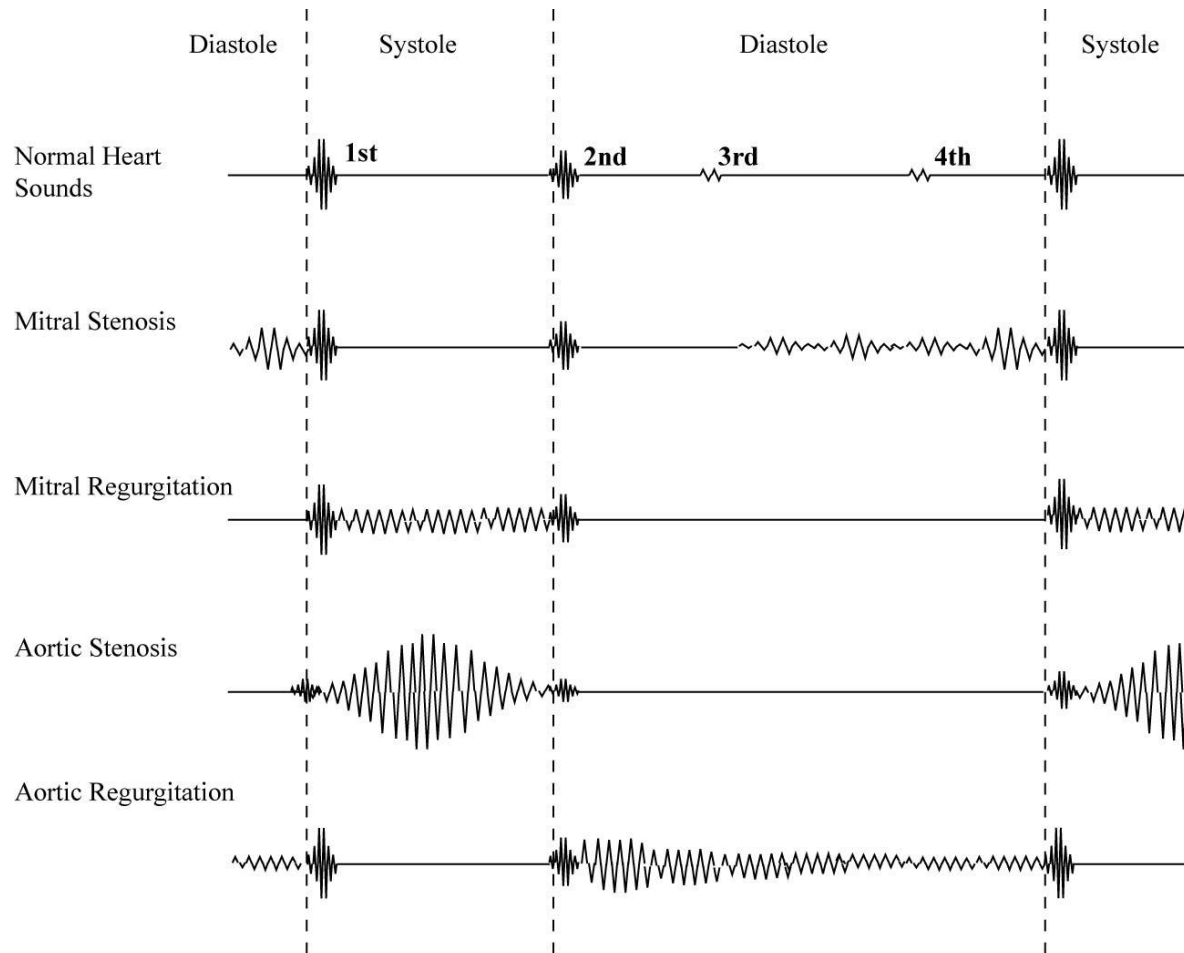


Heart murmurs - grade

- I - faint, heard only with special effort
- II – soft
- III – loud
- IV – loud with thrill
- V – audible with stethoscope barely touching the chest
- VI – murmur audible without the stethoscope



Heart murmurs



Case 9

- 87-year old male with a history of hypertension and ischemic heart disease, after a STEMI of inferior wall treated with PCI of the right coronary artery was brought to the ER after another loss of consciousness. Loss of consciousness reoccurred for two days before admission, were preceded by a sensation of slow, forced heart beats and dizziness. The patient has no memory of the falls, but he regained consciousness after a few seconds, with no urine or stool incontinence, seizures or tongue bites.



Case 9

- HR 30/min, BP 150/80, temp 36.5 °C, RR 15/min, sat 93%
- Head and neck: pale skin
- Heart: regular heartbeats, first and second heart sounds normal, pansystolic murmur with the maximum intensity at the left lower sternal border.
- Lungs: crackles over lower lobes of both lungs.
- Pitting, symmetrical lower limb oedema.



Bradycardia – suspicion of complete atrio-ventricular block



Case 10

- 58-old male, a smoker, with a history of diabetes and renal disease present to the ER because of heaviness and pressure in the chest not responding to administration of nitroglycerin sublingually with numbness of both arms, shortness of breath, sweating and nausea. For two weeks the patient had recurring similar chest pain of lower intensity upon decreasing amount of exercise, and upon exposure to cold air.



Case 10

- HR 60/min, BP 120/70, temp 36.9 °C, RR 18/min, sat 98%
- Head and neck: pale, sweaty skin
- Heart: regular heartbeats, heart sounds of normal intensity and pronunciation, no murmurs
- Lungs: normal



Myocardial infarction preceded by angina crescendo



Case 11

- 24-year old male with a history of tuberculosis present to the ER with dyspnea of sudden onset with right side chest pain after a fall from the ladder. The pain is sharp, localized at the III intercostal space in posterior axillary line, and its aggravated by breathing.



Case 11

- HR 140/min, BP 80/50, temp 36.9 °C, RR 40/min, sat 80%
- Head and neck: pale, sweaty skin, trachea deviating to the left,
- Heart: regular heartbeats, heart sounds of normal intensity and pronunciation, no murmurs
- Lungs: decreased tactile fremitus, hyperresonance on percussion on the right side of the thorax, lack of breath sound over the right lung, normal breathing sounds over the left lung



Right side pneumothorax



Traditional clinical classification of chest pain

Typical angina (definite)	Meets all three of the following characteristics: <ul style="list-style-type: none">• substernal chest discomfort of characteristic quality and duration;• provoked by exertion or emotional stress;• relieved by rest and/or nitrates within minutes.
Atypical angina (probable)	Meets two of these characteristics.
Non-anginal chest pain	Lacks or meets only one or none of the characteristics.



Classification of angina severity according to the Canadian Cardiovascular Society

Class I	Ordinary activity does not cause angina such as walking and climbing stairs. Angina with strenuous or rapid or prolonged exertion at work or recreation.
Class II	Slight limitation of ordinary activity. Angina on walking or climbing stairs rapidly, walking or stair climbing after meals, or in cold, wind or under emotional stress, or only during the first few hours after awakening. Walking more than two blocks on the level and climbing more than one flight of ordinary stairs at a normal pace and in normal conditions.
Class III	Marked limitation of ordinary physical activity. Angina on walking one to two blocks ^a on the level or one flight of stairs in normal conditions and at a normal pace.
Class IV	Inability to carry on any physical activity without discomfort, angina syndrome may be present at rest.

^aEquivalent to 100–200 m.



Symptoms and signs typical of heart failure (1)

Symptoms	Signs
<i>Typical</i>	<i>More specific</i>
Breathlessness	Elevated jugular venous pressure
Orthopnoea	Hepatojugular reflux
Paroxysmal nocturnal dyspnoea	Third heart sound (gallop rhythm)
Reduced exercise tolerance	Laterally displaced apical impulse
Fatigue, tiredness, increased time to recover after exercise	Cardiac murmur
Ankle swelling	



Symptoms and signs typical of heart failure (2)

Symptoms	Signs
<i>Less typical</i>	<i>Less specific</i>
Nocturnal cough	Peripheral oedema (ankle, sacral, scrotal)
Wheezing	Pulmonary crepitations
Weight gain (>2 kg/week)	Reduced air entry and dullness to percussion at lung bases (pleural effusion)
Weight loss (in advanced heart failure)	Tachycardia
Bloated feeling	Irregular pulse
Loss of appetite	Tachypnoea (>16 breaths/min)
Confusion (especially in the elderly)	Hepatomegaly
Depression	Ascites
Palpitations	Tissue wasting (cachexia)
Syncope	

